

Use of high-power diode laser at 1060 nm for the treatment of vascular lesions

Gabriel Buendía Bordera, MSc,^a Jorge Gaviria Parada, MD,^a Maribel Martí Giménez, MD,^a María de los Llanos Pérez, MSc,^b Júlia Oliva Morell, BS,^b and Gregorio Viera Mármol, PhD,^c *Barcelona, Spain*

ABSTRACT

The use of 1060-nm wavelength light emitted from a high-power diode laser is a novel method for the removal of vascular lesions. Two Caucasian women with Fitzpatrick skin phototype II, who had various vascular lesions, were treated with a 1060-nm high-power diode laser, applying a fluence of 120 J/cm² and a single pulse duration of 74 milliseconds. Immediate results were that the cherry angiomas became dark and a scab was formed (that remitted 2 weeks after treatment); the telangiectasias and venulectasias disappeared immediately. This technology has reported effective and safe results for removing different types of vascular lesions in the two patients treated. Side effects were those expected for this technique. (*J Vasc Surg Cases and Innovative Techniques* 2019;5:415-8.)

Keywords: Vascular lesions; Cherry angiomas; Telangiectasias; Venulectasias; Nd: YAG; High-power diode laser

The removal of varicose veins and other superficial vascular lesions (telangiectasias, matting, angiomas or cherry angiomas, etc) by laser has been widely described in research and the scientific literature. Although several wavelengths have been tested across the visible spectrum and up to infrared, until now the gold standard has been laser treatment with an neodymium yttrium aluminum garnet laser (Nd:YAG) at 1064 nm with fluences above 100 J/cm² and pulse durations between 20 and 60 milliseconds.^{1,2} This is an effective and safe procedure provided it is performed by an expert capable of establishing the appropriate pulse energies and durations for the dimensions of the blood vessel that is to be photocoagulated.^{3,4} Owing to the spontaneous tendency of the vessel to revascularize, the treatment may require an average of three to five sessions for the complete elimination of the vessel to be achieved, and can be carried out on all phototypes.

Aside from solid-state lasers, high-power diode lasers with wavelengths ranging between 808 and 980 nm have been tested with varying results.^{5,6} Therefore, until now there has been no cases in which a semiconductor laser with gold standard solid-state specifications has been used. The diode laser wavelength in the 1060-nm

range is considered to provide the best ratio of appropriate heating of the hemoglobin in the vascular lesions and weak absorption of the melanin pigment in the skin and hair.⁷

Owing to the high fluences and relatively long pulse durations, this treatment can cause pain despite its safety. Common side effects include darkening or whitening of the vessel or ruby point and erythema formation that persists for 24 hours. Eventually, it can produce a slight transitory edema. The patients who participate in this case report provided written informed consent.

CASE PRESENTATION

Two patients—a 47-year-old woman (patient one) and a 48-year-old woman (patient two)—both of Caucasian origin presented several superficial vascular lesions on the back (cherry angiomas) and the lower limbs (venulectasias and telangiectasias). After the diagnosis and anamnesis, a laser photocoagulation session was performed with a 1060-nm Primelase Excellence Diode (Cocoon Medical, Barcelona, Spain), with a laser spot of 10 × 10 mm², single pulse at a fluence of 120 J/cm² in auto mode (duration and pulse of 74 milliseconds). This device is approved for the removal of vascular lesions under directive 93/42/EEC for medical devices by the notified body N°0051 and certificate number 1604/MDD. However, its most common use is for hair removal treatments.

For each vascular lesion, the skin was cooled to 5°C with the cold sapphire tip of the diode applicator for 1 to 3 seconds to make the treatment more tolerable and provide an initial prophylaxis by cryoprotection in the tissue surrounding the vessel and then a single shot was performed (Figs 1 and 2). This procedure was repeated to cover all vascular lesions and took several minutes. Patients experienced moderate pain during the procedures owing to the size of the spot; however, it was well-tolerated. After the treatment, a corticoid-containing foam was applied to relieve the discomfort and to limit the duration of the erythema.

From the Laser Photomedicine Institute^a; and the Clinical Department,^b and Scientific Department,^c Cocoon Medical.

Author conflict of interest: Some of the authors of this publication research in Cocoon Medical, which develops products related to the research being reported. However, the manuscript was written impartially.

Correspondence: Gregorio Viera Mármol, PhD, Cocoon Medical, Passatge Masoliver 24 08005, Barcelona, Spain (e-mail: gregorioviera@cocoonmedical.com).

The editors and reviewers of this article have no relevant financial relationships to disclose per the Journal policy that requires reviewers to decline review of any manuscript for which they may have a conflict of interest.

2468-4287

© 2019 The Author(s). Published by Elsevier Inc. on behalf of Society for Vascular Surgery. This is an open access article under the CC BY-NC-ND license (<http://creativecommons.org/licenses/by-nc-nd/4.0/>).

<https://doi.org/10.1016/j.jvscit.2019.06.015>

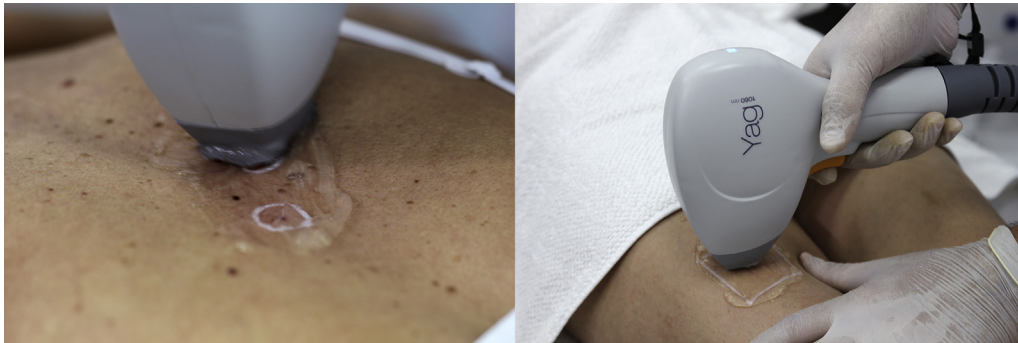

Fig 1. Cherry angiomas on the back (left) and telangiectasias on the legs (right) irradiated with a 1060 nm diode laser applicator using a simple pulse of 120 J/cm² and 74 milliseconds.



Fig 2. Patient one. Cherry angiomas before (left) and immediately after (right) the treatment.

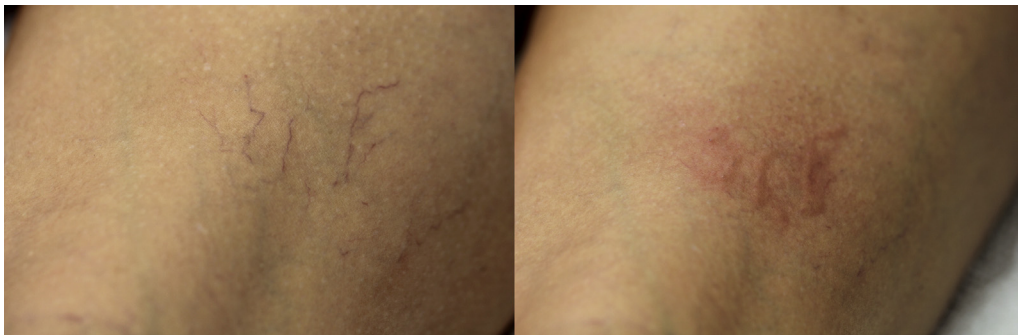


Fig 3. Patient one. Telangiectasias before (left) and immediately after (right) the treatment.

Figs 2 and 3 show the immediate results of the treatment for patient one with cherry angiomas located on the back and three telangiectasias located on the leg.

RESULTS

The vascular lesions reacted positively to the applied light stimulation. Cherry angiomas became dark immediately and telangiectasias disappeared, leaving behind an erythema with the shape of the vessel, which had disappeared by the 24-hour mark. The darkening of the cherry angiomas was followed by the formation of a

scab over the 3-day follow-up, which spontaneously peeled during the second week after treatment.

Patient two had venulectasias located in the popliteal area that disappeared immediately, although the presence of a cord consisting of the photocoagulated vein was perceivable to the touch. The results after 2 weeks can be observed in Figs 4-6.

DISCUSSION

In recent years, several laser systems (long-pulse and long-pulse Alexandrite, long-pulse Nd:YAG KTP, pulsed dye laser, 810-, 940-, and 980-nm diodes) have been

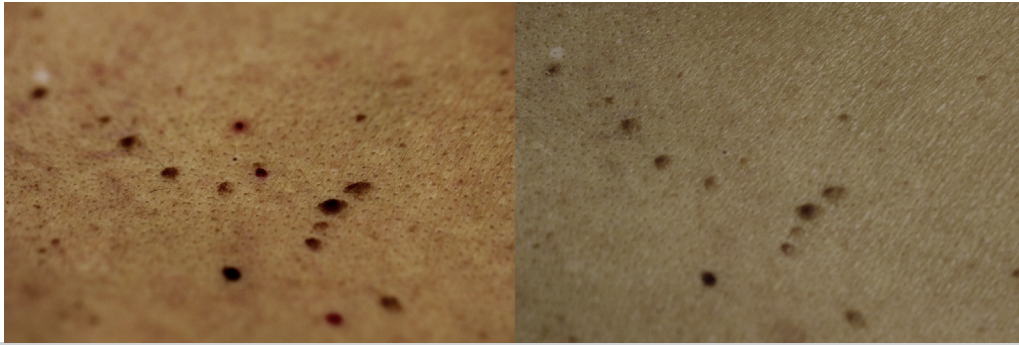


Fig 4. Patient one. Cherry angiomas before (left) and after (right) treatment.

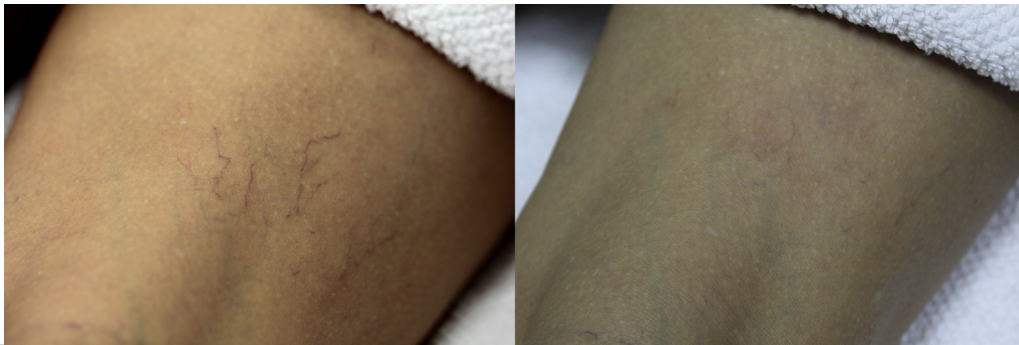


Fig 5. Patient one. Telangiectasias before (left) and after (right) treatment.

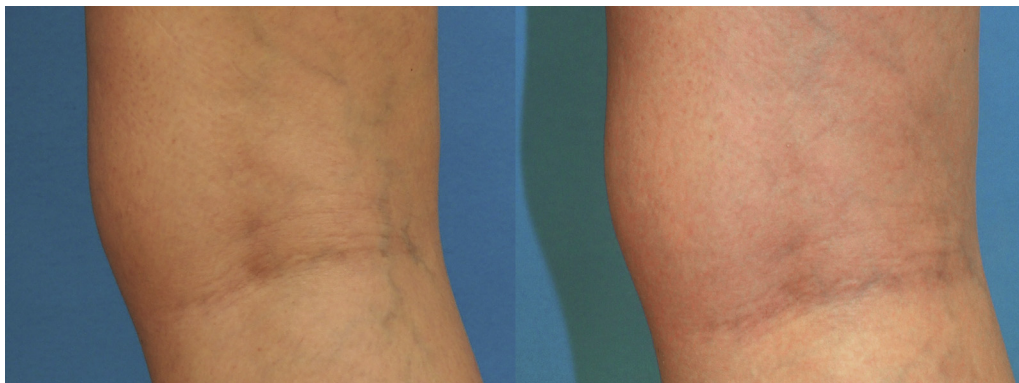

Fig 6. Patient two. Venulectasias before (left) and after (right) treatment.

used with relative success in the treatment of vascular lesions. None have surpassed or even equaled the results of the Nd:YAG at 1064 nm, and, in addition, tend to involve more problems.^{1,2,8,9} The key aspect of these results lies in the ability to emit large amounts of energy in pulses of a few tenths of a millisecond, because hemoglobin is not a static target but circulates through the vessels. Until now, these issues have imposed a technological constraint on the time of use of semiconductor-based lasers,^{1,6} which is why the appearance of a high-power diode laser at 1060 nm capable of emulating a solid-state laser while maintaining the

virtues of the diodes (shooting frequency, cooling through applicator contact, minimum maintenance) is so interesting. Furthermore, for some types of lesions, such as venulectasias, it can provide greater comfort during use by combining a large spot size ($10 \times 10 \text{ mm}^2$) that covers a larger area of the lesion with an applicator that can slide easily and optimal parameters for large vessels.

Logically, these cases only prove that a diode can emulate an Nd:YAG laser in terms of its efficacy and safety as well as its risks, and, as a result, rare but serious complications can be caused when untrained personnel use this technology incorrectly.¹⁰

The 1060-nm wavelength is absorbed by the deoxygenated hemoglobin circulating in the vessels. The selected pulse duration will be determined by the diameter of the vessel being eliminated, because the thermal dissipation time will depend to a large extent on its size. In vascular lesions, the blood flow itself contributes to cooling our target, which is why we must use fluences of greater than 100 J/cm², where smaller telangiectasias would require higher fluences than cherry angioma or venulectasias. The problem is that melanin and water also act as a target at 1060 nm, so it is inevitable that the surrounding tissues will warm to a certain extent. For this reason, it is advisable not to overlap or perform double shots, because, despite the specificity of the heating of the blood, the accumulation of heat can lead to burning of the skin. This consideration aside, the disappearance of the vessels can be observed, leaving behind an erythema with the same shape. In the best case scenario, the collapsed necrotic vessel will be broken down by macrophages. Typically, part of the inflammatory response associated with the photo-coagulation includes angiogenic signals that lead to partial revascularization and, therefore, several sessions have been found to be necessary. Regarding post-treatment care, avoiding sun exposure for between 10 and 15 days is recommended, even with SPF 50 protection. If additional sessions are required, it is recommended that at least 45 days are allowed to elapse after the previous session.

CONCLUSIONS

The feasibility of vascular lesion elimination with a 1060-nm high-power diode laser has been demonstrated in two patients with no major side effects. The procedure was effective and safe and it represents the appearance of a new therapeutic alternative for this indication, however, data with more patients are needed to support this conclusion.

We are grateful to the members of the Instituto Laser de Fotomedicina of Teknon Hospital and also to patients, who provided written informed consent, for their collaboration.

REFERENCES

1. Eremia S, Li C, Umar SH. A side-by-side comparative study of 1064 nm Nd:YAG, 810 nm diode and 755 nm alexandrite lasers for treatment of 0.3-3 mm leg veins. *Dermatol Surg* 2002;28:224-30.
2. Rogachefsky AS, Silapunt S, Goldberg DJ. Nd:YAG laser (1064 nm) irradiation for lower extremity telangiectases and small reticular veins: efficacy as measured by vessel color and size. *Dermatol Surg* 2002;28:220-3.
3. Anderson RR, Parrish JA. Selective photothermolysis: precise microsurgery by selective absorption of pulsed radiation. *Science* 1983;220:524-7.
4. Drosner M, Adatto M; European Society for Laser Dermatology. Photo-epilation: guidelines for care from the European Society for Laser Dermatology (ESLD). *J Cosmet Laser Ther* 2005;7:33-8.
5. Trelles MA, Allones I, Alvarez J, Vélez M, Martín-Vázquez M, Trelles OR, et al. The 800-nm diode laser in the treatment of leg veins: assessment at 6 months. *J Am Acad Dermatol* 2006;54:282-9.
6. Passeron T, Olivier V, Duteil L, Desruelles F, Fontas E, Ortonne JP. The new 940-nanometer diode laser: an effective treatment for leg venulectasia. *J Am Acad Dermatol* 2003;48:768-74.
7. Fodor L, Ullman Y, Elman M. Aesthetic applications of intense pulsed light. In: *Light tissue interactions*. New York: Springer; 2011. p. 11-20.
8. Omura NE, Dover JS, Arndt KA, Kauvar AN. Treatment of reticular leg veins with a 1064 nm long-pulsed Nd:YAG laser. *J Am Acad Dermatol* 2003;48:76-81.
9. Nelson JS, Milner TE, Anvari B, Tanenbaum BS, Svaasand LO, Kimel S. Dynamic epidermal cooling in conjunction with laser-induced photothermolysis of port wine stain blood vessels. *Lasers Surg Med* 1996;19:224-9.
10. Parlette EC, Groff WF, Kinshella MJ, Domankevitz Y, O'Neill J, Ross EV. Optimal pulse durations for the treatment of leg telangiectasias with a neodymium YAG laser. *Lasers Surg Med* 2006;38:98-105.

Submitted Apr 3, 2019; accepted Jun 19, 2019.